

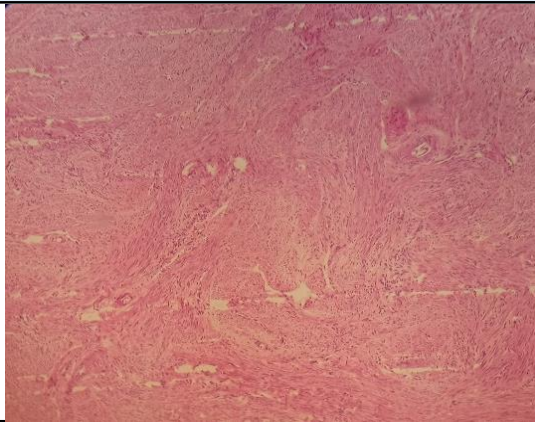
Patient Name	Mrs. SAIDA MUKHAMEDEVA	Client Name	Polaris Hospital	Specimen Received	25/10/19
Age/Sex	44 YRS/F			Specimen Type	Tissue
Patient ID	011910250055			Collection Date	25/10/19
Specimen ID	MOLQ/B-2023/19			Report Date	28/10/19

SURGICAL PATHOLOGY REPORT

Uterus with Cervix

DIAGNOSIS

Leiomyoma



SPECIMEN

Uterus with Cervix

GROSS

Received 9.5x6.5 cm uterus with cervix and cervix shows Nabothian cyst. Cut section shows 2x2cm fibroid.

Microscopy


Section examined shows

- 1)Endometrium with proliferative phase
- 2)Myometrium with muscle bundles
- 3)Cervix with mononuclear inflammatory cells
- 4)Fibroid with interlacing muscle bundles

Note : All biopsy specimen will be stored for 15 (fifteen)days, block and slides for 5(five) years only from the time of receipt at the laboratory. No request ,for any of the above ,will be entertained after the due date.

Reference

- i) Rosai and Ackerman's Surgical Pathology.
- ii) Modern Surgical Pathology.


Gulshan Yadav, MD
Consultant Pathologist