

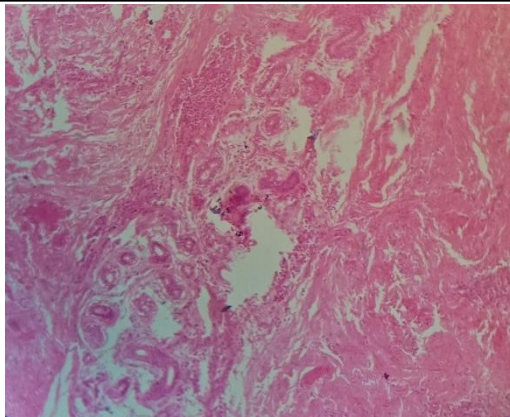
Patient Name	Mr. KAWAL SINGH	Client Name	Umkal Hospital	Specimen Received	24/10/19
Age/Sex	31 YRS/M			Specimen Type	Tissue
Patient ID	011910240134			Collection Date	24/10/19
Specimen ID	MOLQ/B-2022/19			Report Date	28/10/19

SURGICAL PATHOLOGY REPORT

Perianal tissue

DIAGNOSIS

Non Specific Inflammation



SPECIMEN

Perianal tissue

GROSS

Received multiple grayish white tissue piece.


Microscopy

Section examined shows squamous lining epithelium large number of inflammatory cells (polymorphs, lymphocytes, pus cells) and blood vessels. No granuloma and no malignant cells seen.

Note : All biopsy specimen will be stored for 15 (fifteen)days, block and slides for 5(five) years only from the time of receipt at the laboratory. No request ,for any of the above ,will be entertained after the due date.

Reference

- i) Rosai and Ackerman's Surgical Pathology.
- ii) Modern Surgical Pathology.


Gulshan Yadav, MD
Consultant Pathologist