

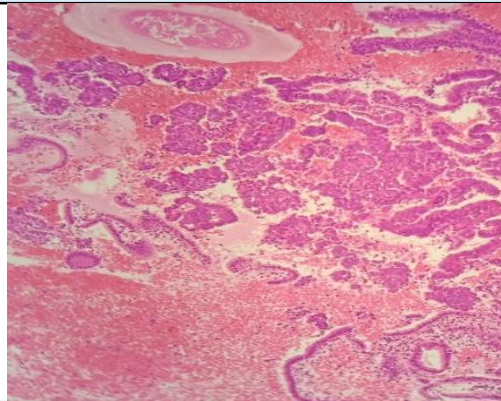
Patient Name	Mrs. MEENA W/O AJAY	Client Name	Path Star Diagnostic	Specimen Received	21/10/2019
Age/Sex	40YRS/F			Specimen Type	Tissue
Patient ID	011910210207			Collection Date	21/10/2019
Specimen ID	MOLQ/B-2000/19(2)			Report Date	26/10/2019

SURGICAL PATHOLOGY REPORT

Endometrium

DIAGNOSIS

PROLIFERATIVE PHASE



SPECIMEN

Endometrium

GROSS

Received multiple grayish white tissue piece.

Microscopy

Section examined shows small endometrial glands with cuboidal to columnar lining epithelium with small round nucleus. Stroma shows mononuclear inflammatory cells.

No granuloma seen. No malignant cells seen.

Note : All biopsy specimen will be stored for 15 (fifteen) days, block and slides for 5 (five) years only from the time of receipt at the laboratory. No request ,for any of the above ,will be entertained after the due date.

Reference

- i) Rosai and Ackerman's Surgical Pathology.
- ii) Modern Surgical Pathology.

Gulshan Yadav, MD
Consultant Pathologist