

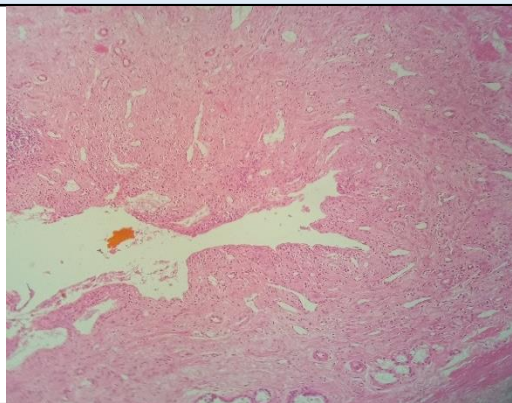
Patient Name	Mrs. MEENA W/O AJAY	Client Name	Path Star Diagnostic	Specimen Received	21/10/2019
Age/Sex	40YRS/F			Specimen Type	Tissue
Patient ID	011910210207			Collection Date	21/10/2019
Specimen ID	MOLQ/B-2000/19(1)			Report Date	26/10/2019

SURGICAL PATHOLOGY REPORT

Gall Bladder

DIAGNOSIS

CHOLECYSTITIS AND CHOLELITHIASIS.



SPECIMEN

Gall Bladder

GROSS

Received 6.2x2.3cm long gall bladder. Cut section shows stones wall thickness 0.3 mm.

Microscopy

Section examined shows ulcerative mucosa and rokitansky aschoff sinus (irregularly shaped tubular structures lined by cuboidal lining epithelium with round to oval nucleus) with fibro collagenous tissue and inflammatory cells (lymphocytes). No granuloma and no malignant cells seen.

Note : All biopsy specimen will be stored for 15 (fifteen)days, block and slides for 5(five) years only from the time of receipt at the laboratory. No request ,for any of the above ,will be entertained after the due date.

Reference

- i) Rosai and Ackerman's Surgical Pathology.
- ii) Modern Surgical Pathology.

Gulshan Yadav, MD
Consultant Pathologist