

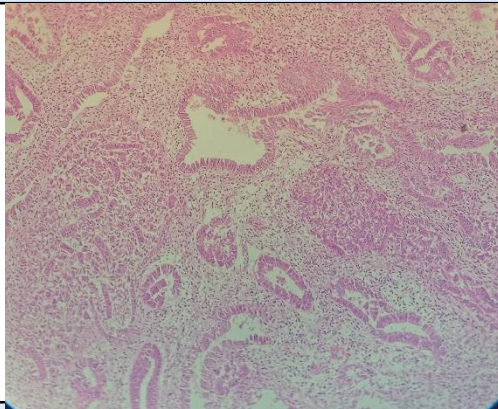
<b>Patient Name</b>	Mrs. SHARMILA DEVIDAS	<b>Client Name</b>	Goyal Nursing Home (Palwal)	<b>Specimen Received</b>	21/10/2019
<b>Age/Sex</b>	39 YRS/F	<b>Specimen Type</b>		<b>Collection Date</b>	21/10/2019
<b>Patient ID</b>	011910210163	<b>Report Date</b>			26/10/2019
<b>Specimen ID</b>	MOLQ/B-1996/19				

**SURGICAL PATHOLOGY REPORT**

Uterus with Cervix

**DIAGNOSIS**

**CHRONIC CERVICITIS WITH ENDOMETRIAL POLYP.**



**SPECIMEN**

Uterus with Cervix

**GROSS**

Received 8.5x6 cm uterus with cervix cut section shows 1x1cm endometrial polyp.

**Microscopy**

Section examined shows

- 1)Endometrium with proliferative phase
  - 2)Myometrium with muscle bundles
  - 3)Cervix with mononuclear inflammatory cells
  - 4) Endometrial polyp shows large number inflammatory cells( polymorphs, lymphocytes, pus cells).
- Section also shows endometrial glands with round nucleus. Stroma shows mononuclear inflammatory cells.

**Note :** All biopsy specimen will be stored for 15 (fifteen)days, block and slides for 5(five) years only from the time of receipt at the laboratory. No request ,for any of the above ,will be entertained after the due date.

**Reference**

- i) Rosai and Ackerman's Surgical Pathology.
- ii) Modern Surgical Pathology.

**Gulshan Yadav, MD  
Consultant Pathologist**