

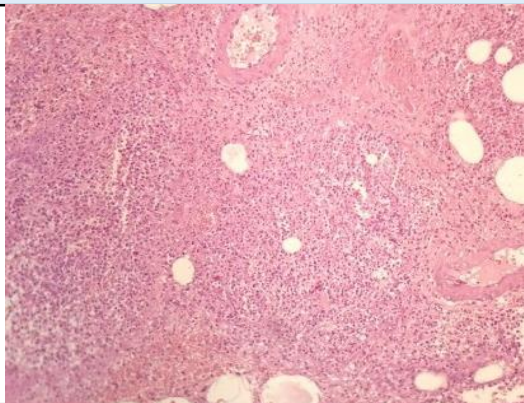
Patient Name	Mr. KARTAR	Client Name	Goyal Nursing Home (Palwal)	Specimen Received	21/10/2019
Age/Sex	48 YRS/M			Specimen Type	Tissue
Patient ID	011910210147			Collection Date	21/10/2019
Specimen ID	MOLQ/B-1994/19			Report Date	26/10/2019

SURGICAL PATHOLOGY REPORT

Appendix

DIAGNOSIS

ACUTE APPENDICITIS



SPECIMEN

Appendix

GROSS

Received 5X1.1 cm long appendix. Cut section shows feco-lith.

Microscopy

- Section examined shows lymphoid follicles with ulcerative mucosa. Deeper tissue shows inflammatory cells (polymorphs and lymphocytes). No granuloma seen. No malignant cells seen.

Note : All biopsy specimen will be stored for 15 (fifteen)days, block and slides for 5(five) years only from the time of receipt at the laboratory. No request ,for any of the above ,will be entertained after the due date.

Reference

- Rosai and Ackerman's Surgical Pathology.
- Modern Surgical Pathology.

Gulshan Yadav, MD
Consultant Pathologist