

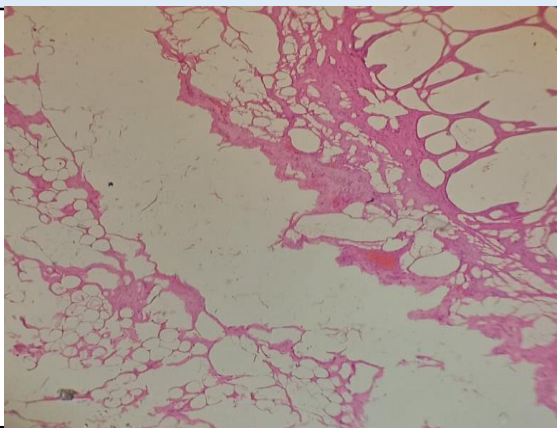
Patient Name	Mrs. SHAHEENA / PAMPORE	Client Name	A-One Collection Centre,	Specimen Received	21/10/19
Age/Sex	35 Years/Female	Jammu & Kashmir		Specimen Type	Tissue
Patient ID	041910210004			Collection Date	21/10/19
Specimen ID	MOLQ/B-1991/19			Report Date	25/10/19

SURGICAL PATHOLOGY REPORT

Gall Bladder

DIAGNOSIS

CHRONIC CHOLECYSTITIS AND CHOLELITHIASIS.



SPECIMEN

Gall Bladder

GROSS

Received 6.2x2.1cm long gall bladder. Cut section shows tiny stones.

Microscopy

Section examined shows ulcerative mucosa and Rokitansky-Aschoff sinuses (irregularly shaped tubular structures lined by cuboidal lining epithelium with round to oval nucleus) with fibrocollagenous tissue and inflammatory cells (lymphocytes). No granuloma and no malignant cell seen.

Note : All biopsy specimen will be stored for 15 (fifteen) days, block and slides for 5 (five) years only from the time of receipt at the laboratory. No request, for any of the above, will be entertained after the due date.

Reference

- Rosai and Ackerman's Surgical Pathology.
- Modern Surgical Pathology.

Gulshan Yadav, MD
Consultant Pathologist