

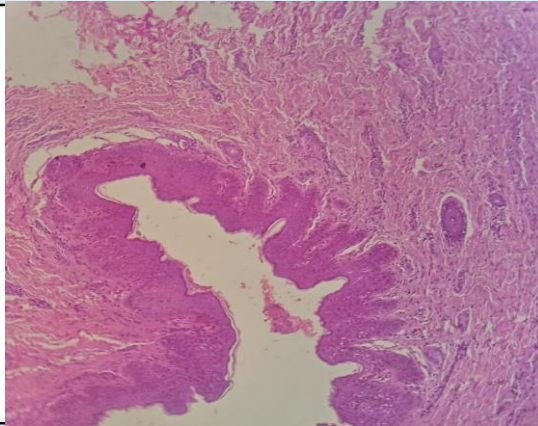
Patient Name	Baby. BHAVYA	Client Name	MolQ CC Greenleaf	Specimen Received	21/10/19
Age/Sex	1 Years/Female	Diagnostic		Specimen Type	Tissue
Patient ID	011910210130			Collection Date	21/10/19
Specimen ID	MOLQ/B-1993/19			Report Date	25/10/19

SURGICAL PATHOLOGY REPORT

Neck swelling

DIAGNOSIS

Chronic Infective Cystic Lesion



SPECIMEN

Neck swelling

GROSS

Received 1.8x1.5cm grayish white tissue piece.

Microscopy

Section examined shows squamous lining epithelium with mild hyperkeratosis. Deeper tissue shows fibro collagenous cells, mature adipose cells and inflammatory cells(lymphocytes, centrocytes and macrophages) with multinucleated giant cells. No well formed granuloma. No malignant cells seen.

Note : All biopsy specimen will be stored for 15 (fifteen)days, block and slides for 5(five) years only from the time of receipt at the laboratory. No request ,for any of the above ,will be entertained after the due date.

Reference

- i) Rosai and Ackerman's Surgical Pathology.
- ii) Modern Surgical Pathology.

Gulshan Yadav, MD
Consultant Pathologist