

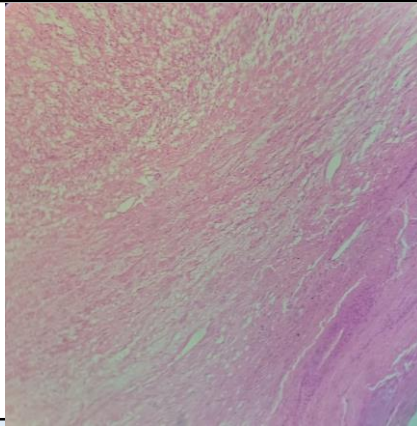
Patient Name	Miss. RAJNI	Client Name	Welcome Hospital Delhi	Specimen Received	20/10/19
Age/Sex	25 Years/Female			Specimen Type	Tissue
Patient ID	011910200159			Collection Date	20/10/19
Specimen ID	MOLQ/B-1987/19			Report Date	25/10/19

SURGICAL PATHOLOGY REPORT

Neurofibroma

DIAGNOSIS

Suggestive of Benign Mesenchymal Lesion (Neurofibroma).



SPECIMEN

Neurofibroma

GROSS

Received 1x1cm grayish white tissue piece.


Microscopy

Section examined shows nerve bundles, large number of blood vessels.
No granuloma and no malignant cells seen.

Note : All biopsy specimen will be stored for 15 (fifteen) days, block and slides for 5 (five) years only from the time of receipt at the laboratory. No request, for any of the above, will be entertained after the due date.

Reference

- i) Rosai and Ackerman's Surgical Pathology.
- ii) Modern Surgical Pathology.


Gulshan Yadav, MD
Consultant Pathologist