

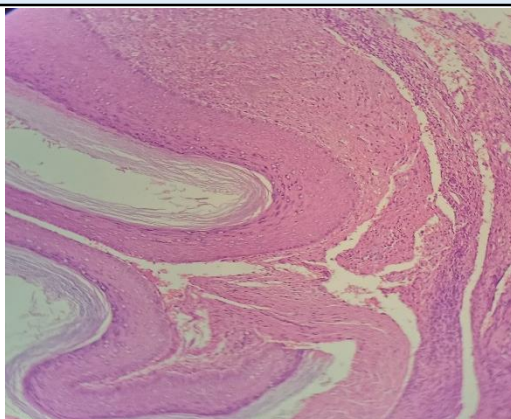
Patient Name	Mr. SATISH KUMAR	Client Name	Lifeaid Wellness Centre	Specimen Received	20/10/19
Age/Sex	44 Years/Male			Specimen Type	Tissue
Patient ID	011910200022			Collection Date	20/10/19
Specimen ID	MOLQ/B-1989/19			Report Date	25/10/19

SURGICAL PATHOLOGY REPORT

Large infected cyst on back

DIAGNOSIS

Infective Cystic Lesion



SPECIMEN

Large infected cyst on back

GROSS

Received 3x3.5 cm long grayish whites tissue piece.

Microscopy

Section examined shows fibro collagenous tissue mature adipose, with inflammatory cells (polymorphs, lymphocytes, plasma cells, macrophages and histiocytes) and large number of blood vessels.

No granuloma no malignant cells seen.

Note : All biopsy specimen will be stored for 15 (fifteen)days, block and slides for 5(five) years only from the time of receipt at the laboratory. No request ,for any of the above ,will be entertained after the due date.

Reference

- Rosai and Ackerman's Surgical Pathology.
- Modern Surgical Pathology.



Gulshan Yadav, MD
Consultant Pathologist