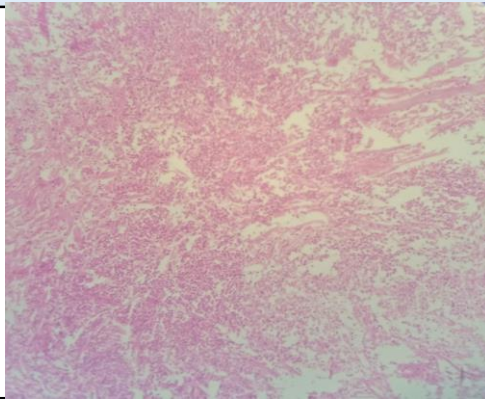


<b>Patient Name</b>	<b>Mrs. MANNI DEVI</b>	<b>Client Name</b>	Cygnus SuperSpeciality	<b>Specimen Received</b>	17/10/19
<b>Age/Sex</b>	65 Years/Female	<b>Hospital, Rewari</b>		<b>Specimen Type</b>	Tissue
<b>Patient ID</b>	011910170244			<b>Collection Date</b>	17/10/19
<b>Specimen ID</b>	MOLQ/B-1975/19			<b>Report Date</b>	22/10/19

## SURGICAL PATHOLOGY REPORT Swelling on back

### DIAGNOSIS

**Infective Lesion.**



#### **SPECIMEN**

Swelling on back

#### **GROSS**

Received two grayish white tissue piece, 4x3.8, 4.3x2.8 cm with skin attached.

#### **Microscopy**

Section examined shows fibro collagenous tissue squamous lining epithelium, blood vessels, glands and large number of inflammatory cells (polymorphs, plasma cells, pus cells) with areas of necrosis.

No granuloma and no malignant cells seen.

**Note :** All biopsy specimen will be stored for 15 (fifteen) days, block and slides for 5 (five) years only from the time of receipt at the laboratory. No request, for any of the above, will be entertained after the due date.

#### **Reference**

- i) Rosai and Ackerman's Surgical Pathology.
- ii) Modern Surgical Pathology.



**Gulshan Yadav, MD**  
Consultant Pathologist