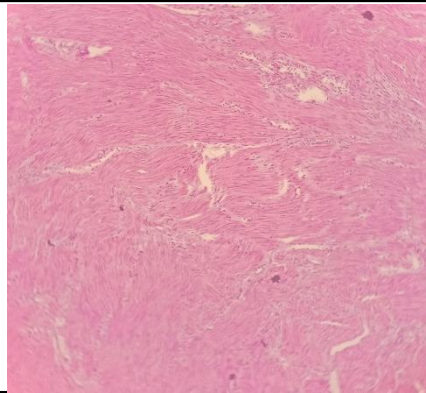


<b>Patient Name</b>	<b>Mrs. GOBHIRA</b>	<b>Client Name</b>	Civil Hospital Sec-10	<b>Specimen Received</b>	16/10/19
<b>Age/Sex</b>	42 Years/Female			<b>Specimen Type</b>	Tissue
<b>Patient ID</b>	011910160265			<b>Collection Date</b>	16/10/19
<b>Specimen ID</b>	MOLQ/B-1968/19			<b>Report Date</b>	22/10/19

## SURGICAL PATHOLOGY REPORT Uterus with Cervix

### DIAGNOSIS

### LEIOMYOMA



#### SPECIMEN

Uterus with Cervix

#### GROSS

Received 10.2x8.5 cm uterus with cervix. Cut section shows 3.2x3.5 cm fibroid.

#### Microscopy


Section examined shows

- 1) Endometrium with proliferative phase
- 2) Myometrium with adenomyosis.
- 3) Cervix with mononuclear inflammatory cells
- 4) Fibroid with interlacing muscle bundles.

**Note :** All biopsy specimen will be stored for 15 (fifteen) days, block and slides for 5 (five) years only from the time of receipt at the laboratory. No request, for any of the above, will be entertained after the due date.

#### Reference

- i) Rosai and Ackerman's Surgical Pathology.
- ii) Modern Surgical Pathology.

  
**Gulshan Yadav, MD**  
Consultant Pathologist