

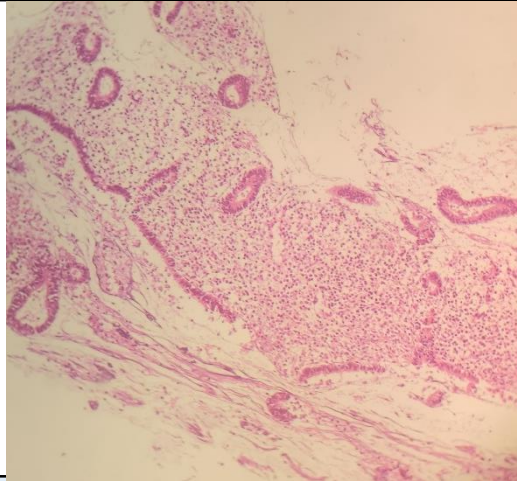
Patient Name	Mrs. WINSIN	Client Name	Prakash Hospital, Gurgaon.	Specimen Received	15-Oct-2019
Age/Sex	33 Years/Female			Specimen Type	Tissue
Patient ID	011910150253			Collection Date	15-Oct-2019
Specimen ID	MOLQ/B-1965/19			Report Date	19-Oct-2019

SURGICAL PATHOLOGY REPORT

Endometrial Biopsy (H/o Bleeding P/V-on and often since 4 months followed by heavy bleeding P/V since 5 days.)

DIAGNOSIS

EARLY SECRETORY PHASE



SPECIMEN

Endometrium

GROSS

Received autolyzed multiple grayish white tissue piece.

Microscopy

1. Section examined shows autolytic changes with small endometrial glands with cuboidal to columnar lining epithelium with small round nucleus. Few glands shows vacuoles and secretions in the lumen.
2. Stroma shows mononuclear inflammatory cells.
3. No granuloma seen. No malignant cells seen.

Note : All biopsy specimen will be stored for 15 (fifteen)days, block and slides for 5(five) years only from the time of receipt at the laboratory. No request ,for any of the above ,will be entertained after the due date.

Reference

- i) Rosai and Ackerman's Surgical Pathology.
- ii) Modern Surgical Pathology.

Gulshan Yadav, MD
Consultant Pathologist