

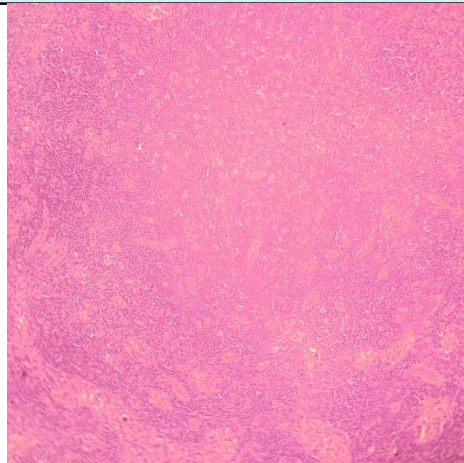
<b>Patient Name</b>	<b>Mrs. MAHENDRI</b>	<b>Specimen Received</b>	13-Oct-2019
<b>Age/Sex</b>	26 Years/Female	<b>Specimen Type</b>	Tissue
<b>Patient ID</b>	011910130225	<b>Client Name</b>	Galaxy Hospital, Palwal
<b>Specimen ID</b>	MOLQ/B-1957/19	<b>Collection Date</b>	13-Oct-2019
		<b>Report Date</b>	18-Oct-2019

## SURGICAL PATHOLOGY REPORT

### Mesenteric Lymph Nodes

#### DIAGNOSIS

**REACTIVE LYMPHADENITIS WITH SINUS HYPERPLASIA.**



#### **SPECIMEN**

Mesenteric Lymph Nodes

#### **GROSS**

Received two lymph nodes measuring 1x0.6 cm, 1.1x0.7 cm.

#### **Microscopy**

1. Section examined shows preserved lymphoid architectures (lymphocytes, centrocytes, centroblasts) and dilated sinuses.
2. Section also shows presence of histiocytes.
3. No granuloma seen. No malignant cells seen.

**Note :** All biopsy specimen will be stored for 15 (fifteen) days, block and slides for 5 (five) years only from the time of receipt at the laboratory. No request, for any of the above, will be entertained after the due date.

#### **Reference**

- i) Rosai and Ackerman's Surgical Pathology.
- ii) Modern Surgical Pathology.

**Gulshan Yadav, MD**  
**Consultant Pathologist**