

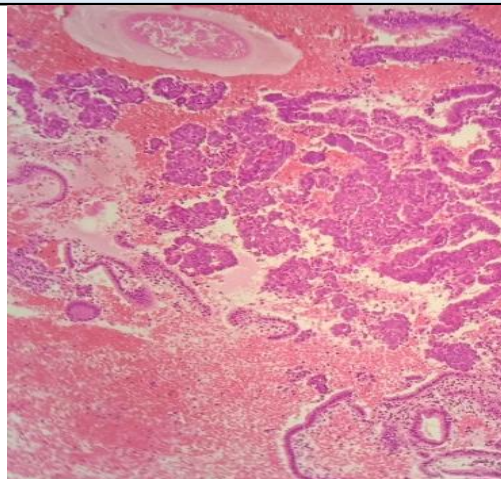
Patient Name	Mrs. ANOKHI	Client Name	Path Star Diagnostic	Specimen Received	14-Oct-2019
Age/Sex	32YRS/F			Specimen Type	Tissue
Patient ID	011910140237			Collection Date	14-Oct-2019
Specimen ID	MOLQ/B-1960/19			Report Date	17-Oct-2019

SURGICAL PATHOLOGY REPORT

Endometrium

DIAGNOSIS

Disordered Proliferative Phase with Hyperprogesteronic Effect.



SPECIMEN

Endometrium

GROSS

Received multiple grayish white tissue piece.

Microscopy

Section examined shows small and tortuous endometrial glands with columnar lining epithelium with small round to oval nucleus and decidualised stroma. No granuloma and no malignant cells seen.

Note : All biopsy specimen will be stored for 15 (fifteen) days, block and slides for 5 (five) years only from the time of receipt at the laboratory. No request, for any of the above, will be entertained after the due date.

Reference

- i) Rosai and Ackerman's Surgical Pathology.
- ii) Modern Surgical Pathology.

Gulshan Yadav, MD
Consultant Pathologist