

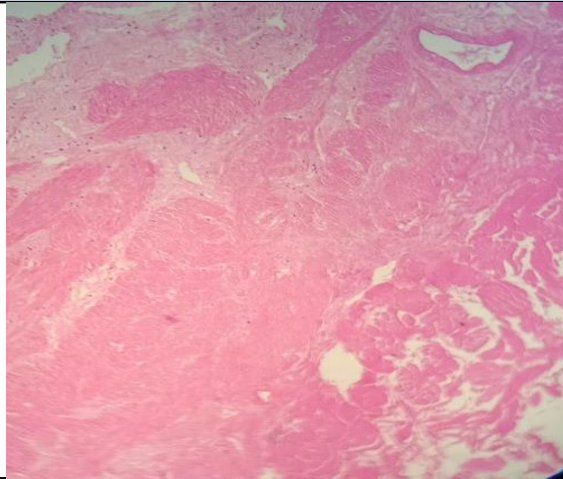
Patient Name	Mrs. JALISHA BEGAM	Client Name	Kriti Hospital	Specimen Received	13-Oct-2019
Age/Sex	50YRS/F			Specimen Type	Tissue
Patient ID	011910130137			Collection Date	13-Oct-2019
Specimen ID	MOLQ/B-1952/19			Report Date	17-Oct-2019

SURGICAL PATHOLOGY REPORT

Gall Bladder

DIAGNOSIS

CHOLECYSTITIS



SPECIMEN

Gall Bladder

GROSS

Received 6.2x2.6cm long gall bladder cut section shows no stones wall thickness 0.3mm.

Microscopy

Section examined shows ulcerative mucosa and Rokitansky-Aschoff sinus (irregularly shaped tubular structures lined by cuboidal lining epithelium with round to oval nucleus) with fibrocollagenous tissue and inflammatory cells (lymphocytes). No granuloma and no malignant cells seen.

Note : All biopsy specimen will be stored for 15 (fifteen) days, block and slides for 5 (five) years only from the time of receipt at the laboratory. No request, for any of the above, will be entertained after the due date.

Reference

- i) Rosai and Ackerman's Surgical Pathology.
- ii) Modern Surgical Pathology.

Gulshan Yadav, MD
Consultant Pathologist