

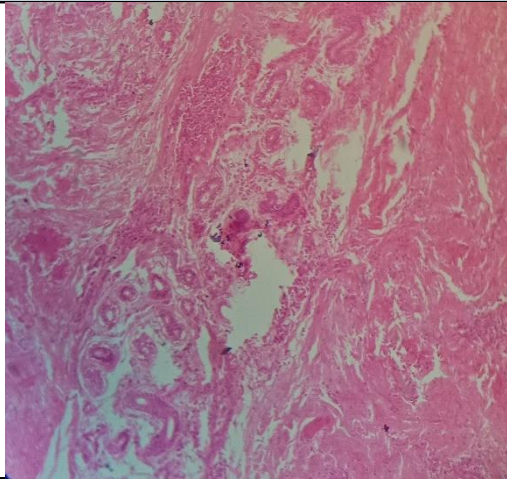
| | | | | | |
|---------------------|------------------------|-------------------------|------------------------|--------------------------|-------------|
| Patient Name | Mr. PAPPU SINGH | Client Name | Cygnus SuperSpeciality | Specimen Received | 11-Oct-2019 |
| Age/Sex | 56 Years/Male | Hospital, Rewari | | Specimen Type | Tissue |
| Patient ID | 011910110346 | | | Collection Date | 11-Oct-2019 |
| Specimen ID | MOLQ/B-1943/19 | | | Report Date | 16-Oct-2019 |

SURGICAL PATHOLOGY REPORT

Fistula in ano rectal area, Perianal sinus

DIAGNOSIS

Non Specific Inflammation



SPECIMEN

Fistula in ano rectal area, Perianal sinus

GROSS

Received multiple grayish white tissue piece with skin with fistula opening

Microscopy

Section examined shows squamous lining epithelium with round to oval nucleus. Deeper tissue shows large number of inflammatory cells(Polymorphs, Lymphocytes).

No granuloma and no malignant cells seen.

Note : All biopsy specimen will be stored for 15 (fifteen)days, block and slides for 5(five) years only from the time of receipt at the laboratory. No request ,for any of the above ,will be entertained after the due date.

Reference

- i) Rosai and Ackerman's Surgical Pathology.
- ii) Modern Surgical Pathology.

Gulshan Yadav, MD
Consultant Pathologist