

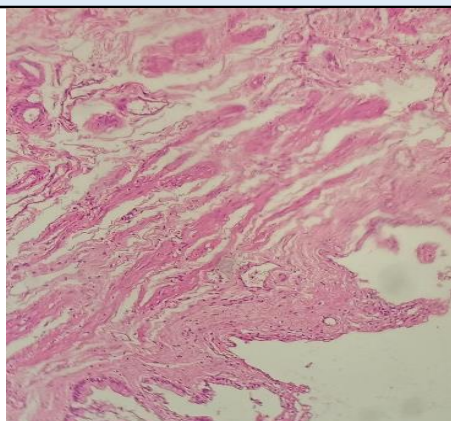
Patient Name	Mrs. PREETI DEVI	Client Name	Goyal Nursing Home	Specimen Received	10/10/19
Age/Sex	29 YRS/F	(Palwal)		Specimen Type	Tissue
Patient ID	011910100285			Collection Date	10/10/19
Specimen ID	MOLQ/B-1936/19			Report Date	15/10/19

SURGICAL PATHOLOGY REPORT

Gall Bladder

DIAGNOSIS

CHOLECYSTITIS AND CHOLELITHIASIS.



SPECIMEN

Gall Bladder

GROSS

Received 6.5x2.4cm long gall bladder. Cut section shows stones. Wall thickness 0.3mm

Microscopy

Section examined shows ulcerative mucosa and Rokitansky-Aschoff sinuses (irregularly shaped tubular structures lined by cuboidal lining epithelium with round to oval nucleus) with fibrocollagenous tissue and inflammatory cells (lymphocytes).

Note : All biopsy specimen will be stored for 15 (fifteen) days, block and slides for 5 (five) years only from the time of receipt at the laboratory. No request, for any of the above, will be entertained after the due date.

Reference

- i) Rosai and Ackerman's Surgical Pathology.
- ii) Modern Surgical Pathology.

Gulshan Yadav, MD
Consultant Pathologist