

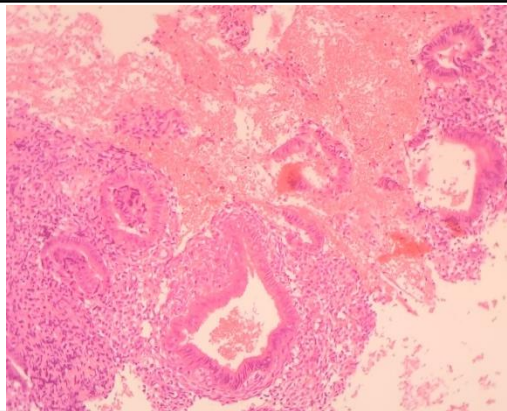
|                     |                      |                          |                    |
|---------------------|----------------------|--------------------------|--------------------|
| <b>Patient Name</b> | Mrs. SUKHWANTI KOHLI | <b>Specimen Received</b> | 12/10/2019         |
| <b>Age/Sex</b>      | 40 Years/Female      | <b>Specimen Type</b>     | Tissue             |
| <b>Patient ID</b>   | 011910120087         | <b>Client Name</b>       | Chirag Diagnostics |
| <b>Specimen ID</b>  | MOLQ/B-1946/19       | <b>Collection Date</b>   | 12/10/2019         |
|                     |                      | <b>Report Date</b>       | 14/10/2019         |

## SURGICAL PATHOLOGY REPORT

Endometrium

### DIAGNOSIS

**PROLIFERATIVE PHASE WITH BLEEDING ENDOMETRIUM.**



#### SPECIMEN

Endometrium

#### GROSS

Received multiple greyish white tissue piece.

#### Microscopy

- Section examined shows small and few cystically dilated glands with lined by columnar lining epithelium having round to oval nucleus with squamous metaplasia with large numbers of RBCs. Stroma shows mononuclear inflammatory cells .
- No granuloma seen. No malignant cells seen.

**Note :** All biopsy specimen will be stored for 15 (fifteen)days, block and slides for 5(five) years only from the time of receipt at the laboratory. No request ,for any of the above ,will be entertained after the due date.

#### Reference

- Rosai and Ackerman's Surgical Pathology.
- Modern Surgical Pathology.

**Gulshan Yadav, MD**  
Consultant Pathologist