

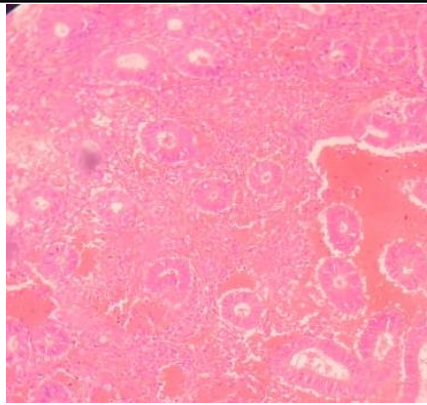
<b>Patient Name</b>	Mrs. SUMAN W/O AJIT YADAV	<b>Client Name</b>	Lalita Memorial Hospital Pvt. Ltd. (Rewari)	<b>Specimen Received</b>	09-Oct-19
<b>Age/Sex</b>	30 Years/Female	<b>Client Code</b>		<b>Specimen Type</b>	Tissue
<b>Patient ID</b>	011910090344	<b>Ref. Doctor</b>		<b>Collection Date</b>	09-Oct-19
<b>Specimen ID</b>	MOLQ/B-1932/19			<b>Report Date</b>	12-Oct-19

## SURGICAL PATHOLOGY REPORT

### Endometrium

#### DIAGNOSIS

#### PROLIFERATIVE PHASE



#### SPECIMEN

Endometrium

#### GROSS

Received multiple grayish white tissue piece.

#### Microscopy

- Section examined shows small endometrial glands having columnar lining epithelium with round to oval nucleus with mild anisonucleosis. Stroma shows inflammatory cells and RBCs. No granuloma and no malignant cells seen. .

**Note :** All biopsy specimen will be stored for 15 (fifteen)days, block and slides for 5(five) years only from the time of receipt at the laboratory. No request ,for any of the above ,will be entertained after the due date.

#### Reference

- Rosai and Ackerman's Surgical Pathology.
- Modern Surgical Pathology.

**Gulshan Yadav, MD  
Consultant Pathologist**