

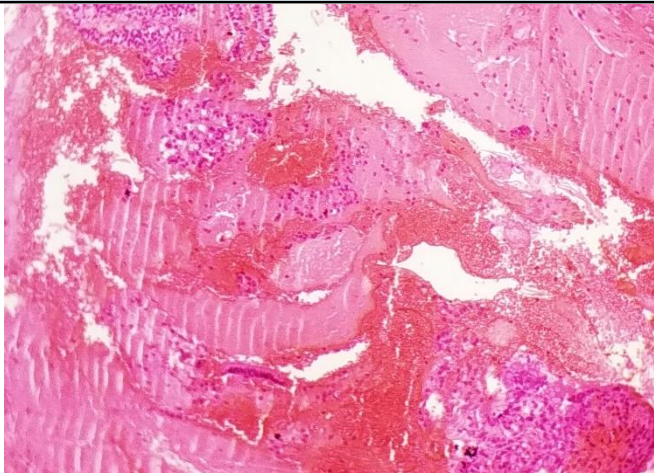
<b>Patient Name</b>	Mrs. SHOBHA	<b>Client Name</b>	Civil Hospital Sec-10	<b>Specimen Received</b>	08-Oct-19
<b>Age/Sex</b>	35 Years/Female			<b>Specimen Type</b>	Tissue
<b>Patient ID</b>	011910080079			<b>Collection Date</b>	08-Oct-19
<b>Specimen ID</b>	MOLQ/B-1919/19			<b>Report Date</b>	12-Oct-19

## SURGICAL PATHOLOGY REPORT

### Cervical Polyp

#### DIAGNOSIS

**Endocervical Polyp.**



#### **SPECIMEN**

Cervical Polyp

#### **GROSS**

Received multiple grayish white tissue piece, 1x1.2 cm in aggregate.

#### **Microscopy**

Section examined shows few broken endocervical glands with cuboidal lining epithelium. Stroma shows mononuclear inflammatory cells. Section also shows squamous lining epithelium round to oval nucleus, RBCs and inflammatory cells. NO granuloma and no malignant cells seen.

**Note :** All biopsy specimen will be stored for 15 (fifteen) days, block and slides for 5 (five) years only from the time of receipt at the laboratory. No request, for any of the above, will be entertained after the due date.

#### **Reference**

- i) Rosai and Ackerman's Surgical Pathology.
- ii) Modern Surgical Pathology.

**Gulshan Yadav, MD**  
**Consultant Pathologist**