

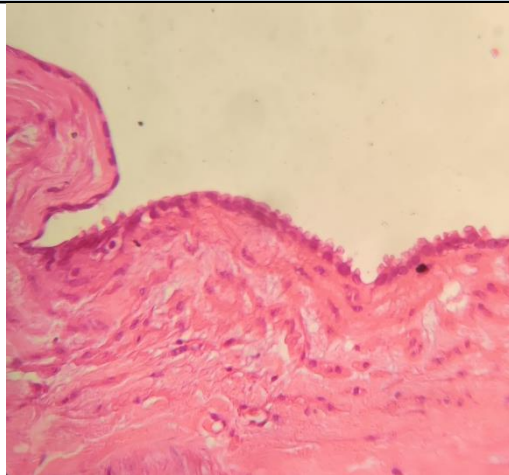
| | | | |
|---------------------|-----------------|--------------------------|-------------------------------------|
| Patient Name | Mrs. RAJ WANTI | Specimen Received | 07-Oct-2019 |
| Age/Sex | 45 Years/Female | Specimen Type | Tissue |
| Patient ID | 011910070208 | Client Name | Lifeaid Wellness Centre, Gurgaon |
| Specimen ID | MOLQ/B-1921/19 | Collection Date | 07-Oct-2019 |
| | | Report Date | 11-Oct-2019 |

SURGICAL PATHOLOGY REPORT

Right Complex Ovarian Cyst

DIAGNOSIS

Simple Ovarian Cyst.



SPECIMEN

Right Complex Ovarian Cyst

GROSS

Received multiple grayish white tissue piece, measuring 5x4 cm in aggregate.

Microscopy

1. Section examined shows cuboidal lining epithelium with round to oval nucleus.
2. Deeper tissue shows fibro collagenous tissue.
3. No granuloma and no malignant cells seen.

Note : All biopsy specimen will be stored for 15 (fifteen) days, block and slides for 5 (five) years only from the time of receipt at the laboratory. No request, for any of the above, will be entertained after the due date.

Reference

- i) Rosai and Ackerman's Surgical Pathology.
- ii) Modern Surgical Pathology.

Gulshan Yadav, MD
Consultant Pathologist