

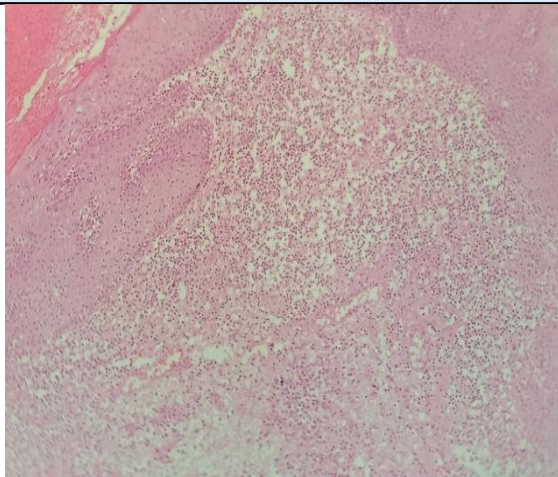
<b>Patient Name</b>	Mr. KISHAN	<b>Client Name</b>	Lifeaid Wellness Centre	<b>Specimen Received</b>	06-10-19
<b>Age/Sex</b>	65 YRS/M			<b>Specimen Type</b>	Tissue
<b>Patient ID</b>	011910060173			<b>Collection Date</b>	06-10-19
<b>Specimen ID</b>	MOLQ/B-1921/19			<b>Report Date</b>	10-10-2019

## SURGICAL PATHOLOGY REPORT

### Fistulctomy

#### DIAGNOSIS

**NON SPECIFIC INFLAMMATION.**



#### **SPECIMEN**

Fistulctomy

#### **GROSS**

Received multiple grayish white tissue piece, measuring 2 x 1.5 cm in aggregate.

#### **Microscopy**

Section examined shows squamous lining epithelium with round to oval nucleus. Deeper tissue shows fibro collagenous tissue and hemorrhagic area, inflammatory cells chiefly composed of lymphocytes, plasma cells polymorphs and large number of blood vessels).

No granuloma and no malignant cells seen.

**Note :** All biopsy specimen will be stored for 15 (fifteen)days, block and slides for 5(five) years only from the time of receipt at the laboratory. No request ,for any of the above ,will be entertained after the due date.

#### **Reference**

- i) Rosai and Ackerman's Surgical Pathology.
- ii) Modern Surgical Pathology.

**Gulshan Yadav, MD**  
Consultant Pathologist