

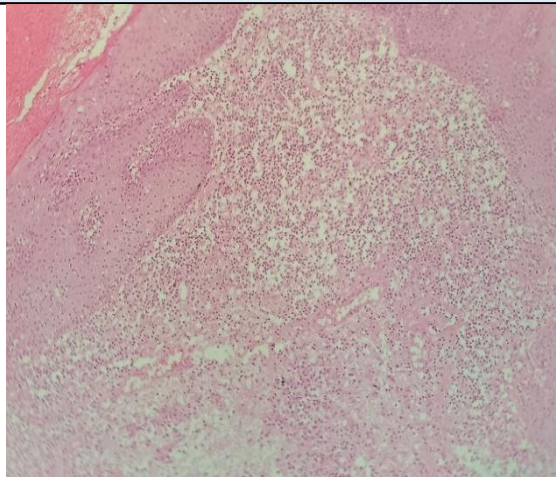
Patient Name	Mr. KISHAN	Client Name	Patient Care Diagnostics,	Specimen Received	06-10-19
Age/Sex	65 YRS/M		Faridabad	Specimen Type	Tissue
Patient ID	011910060173			Collection Date	06-10-19
Specimen ID	MOLQ/B-1918/19			Report Date	10-10-2019

SURGICAL PATHOLOGY REPORT

Fistulctomy

DIAGNOSIS

NON SPECIFIC INFLAMMATION.



SPECIMEN

Fistulctomy

GROSS

Received multiple grayish white tissue piece, measuring 2 x 1.5 cm in aggregate.

Microscopy

Section examined shows squamous lining epithelium with round to oval nucleus. Deeper tissue shows fibro collagenous tissue and hemorrhagic area, inflammatory cells chiefly composed of lymphocytes, plasma cells polymorphs and large number of blood vessels).

No granuloma and no malignant cells seen.

Note : All biopsy specimen will be stored for 15 (fifteen)days, block and slides for 5(five) years only from the time of receipt at the laboratory. No request ,for any of the above ,will be entertained after the due date.

Reference

- i) Rosai and Ackerman's Surgical Pathology.
- ii) Modern Surgical Pathology.

Gulshan Yadav, MD
Consultant Pathologist