

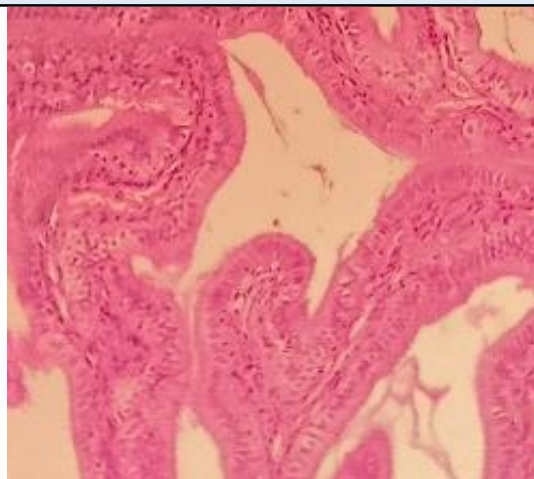
Patient Name	SOBHA DEVI	Client Name	Umkal Hospital	Specimen Received	06-10-19
Age/Sex	48 YRS/F			Specimen Type	Tissue
Patient ID	011910060111			Collection Date	06-10-19
Specimen ID	MOLQ/B-1917/19			Report Date	10-10-2019

SURGICAL PATHOLOGY REPORT

Gall Bladder

DIAGNOSIS

CHOLECYSTITIS.



SPECIMEN

Gall Bladder

GROSS

Received 7x3.8cm long gall bladder already cut open without stones. Wall thickness 0.3 mm.

Microscopy

- Section examined shows autolytic changes with ulcerative mucosa and Rokitansky-Aschoff sinuses (irregularly shaped tubular structures lined by cuboidal lining epithelium with round to oval nucleus) with fibrocollagenous tissue and inflammatory cells (lymphocytes). No granuloma and no malignant cells seen.

Note : All biopsy specimen will be stored for 15 (fifteen) days, block and slides for 5 (five) years only from the time of receipt at the laboratory. No request for any of the above will be entertained after the due date.

Reference

- Rosai and Ackerman's Surgical Pathology.
- Modern Surgical Pathology.

Gulshan Yadav, MD
Consultant Pathologist