

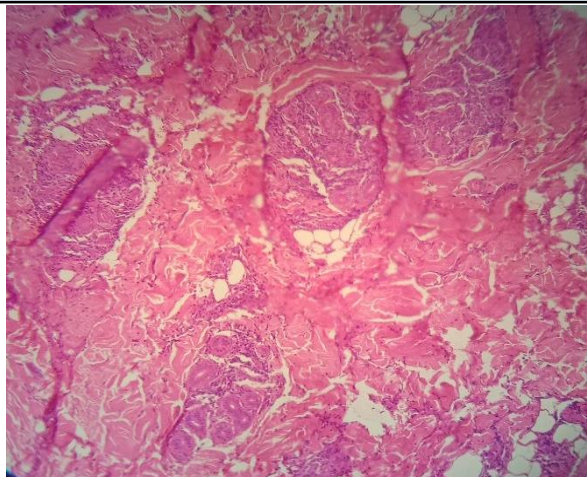
Patient Name	Mr. AJIT	Client Name	Sona Devi Hospital	Specimen Received	05-10-19
Age/Sex	24 YRS/M			Specimen Type	Tissue
Patient ID	011910050158			Collection Date	05-10-19
Specimen ID	MOLQ/B-1913/19			Report Date	09-10-2019

SURGICAL PATHOLOGY REPORT

Swelling on right Pinna

DIAGNOSIS

Sebaceous Cyst



SPECIMEN

Swelling on right Pinna

GROSS

Received 1.2x1cm grayish white cystic tissue piece with skin attached.

Microscopy

Section examined shows squamous lining epithelium with round to oval nucleus with keratosis and Para keratosis and sebaceous glands large number of RBCs and fibro collagenous tissue Few inflammatory cells. No granuloma and no malignant cells seen.

Note : All biopsy specimen will be stored for 15 (fifteen)days, block and slides for 5(five) years only from the time of receipt at the laboratory. No request ,for any of the above ,will be entertained after the due date.

Reference

- i) Rosai and Ackerman's Surgical Pathology.
- ii) Modern Surgical Pathology.

Gulshan Yadav, MD
Consultant Pathologist