

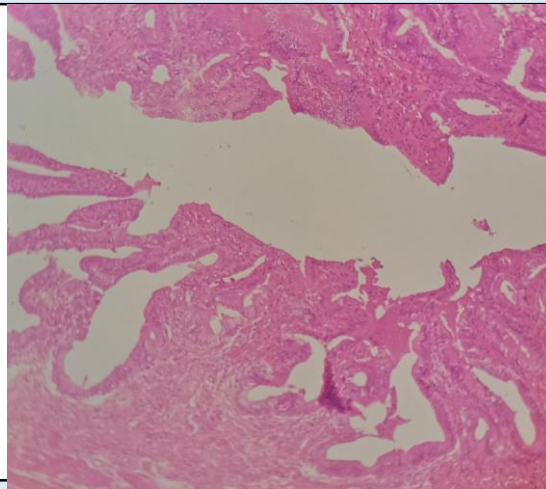
Patient Name	Mrs. RAJRANI	Client Name	Civil Hospital Sec-10	Specimen Received	04-10-19
Age/Sex	56 YRS/F			Specimen Type	Tissue
Patient ID	011910040160			Collection Date	04-10-19
Specimen ID	MOLQ/B-1907/19			Report Date	09-10-2019

SURGICAL PATHOLOGY REPORT

Gall Bladder

DIAGNOSIS

CHOLECYSTITIS.



SPECIMEN

Gall Bladder

GROSS

Received 6x2.9cm long gall bladder without stones.

Microscopy

Section examined shows ulcerative mucosa and Rokitansky-Aschoff sinus (irregularly shaped tubular structures lined by cuboidal lining epithelium with round to oval nucleus) with fibro collagenous tissue and inflammatory cells (lymphocytes).

Note : All biopsy specimen will be stored for 15 (fifteen) days, block and slides for 5 (five) years only from the time of receipt at the laboratory. No request, for any of the above, will be entertained after the due date.

Reference

- i) Rosai and Ackerman's Surgical Pathology.
- ii) Modern Surgical Pathology.

Gulshan Yadav, MD
Consultant Pathologist