

Patient Name	Ms. MUBEENA BANU	Client Name	A-One Collection Centre, J&K	Specimen Received	03-Oct-19
Age/Sex	29 Years/Female			Specimen Type	Tissue
Patient ID	041910030010			Collection Date	03-Oct-19
Specimen ID	MOLQ/B-1901/19			Report Date	07-Oct-19

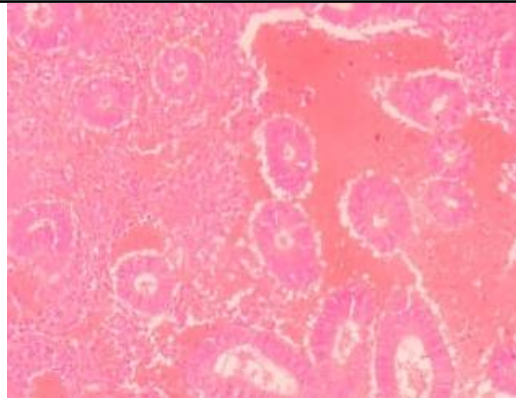
SURGICAL PATHOLOGY REPORT

Endometrium

DIAGNOSIS

Proliferative Phase.

ADVISED: KINDLY, CO-RELATE WITH CLINICAL FINDINGS.



SPECIMEN

Endometrium

GROSS

Received multiple grayish white tissue piece.

Microscopy

- Section examined shows glands with columnar lining epithelium round to oval nucleus few cells shows large nucleus with mild anisonucleosis. Stroma shows mononuclear inflammatory cells. No granuloma and no malignant cells seen.

Note : All biopsy specimen will be stored for 15 (fifteen)days, block and slides for 5(five) years only from the time of receipt at the laboratory. No request ,for any of the above ,will be entertained after the due date.

Reference

- Rosai and Ackerman's Surgical Pathology.
- Modern Surgical Pathology.

Gulshan Yadav, MD
Consultant Pathologist