

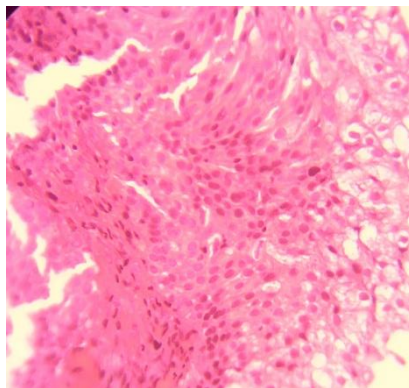
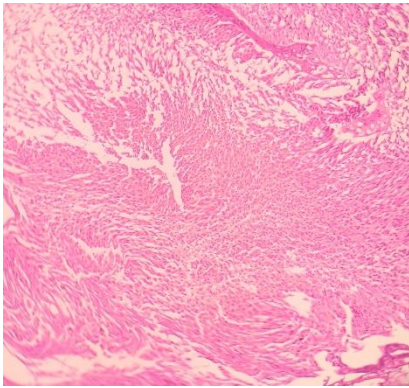
Patient Name	Mrs. SWATRI DEVI 40143	Specimen Received	04-Oct-2019
Age/Sex	72 Years/Female	Specimen Type	Tissue
Patient ID	011910040237	Client Name	Pushpanjali Hospital (Rewari)
Specimen ID	MOLQ/B-1909/19	Collection Date	04-Oct-2019
		Report Date	07-Oct-2019

SURGICAL PATHOLOGY REPORT

TURBT

DIAGNOSIS

LOW GRADE UROTHELIAL CARCINOMA



SPECIMEN

TURBT

GROSS

Received multiple grayish white tissue piece.

Microscopy

Histologic Type:

Urothelial (Transitional Cell) Carcinoma.

Low Grade.

Tumor Configuration:

Solid / Nodule.

Adequacy of Material for Determining Muscularis Propria Invasion.

Muscularis Propria Invasion (Detrusor Muscle):

Invaded.

Lymph vascular Invasion:

Not invaded.

Microscopic extent of tumor:

Tumor invaded subepithelial connective tissue (lamina propria).

Muscularis propria is invaded.

Detrusor muscle not invaded

Note : All biopsy specimen will be stored for 15 (fifteen) days, block and slides for 5 (five) years only from the time of receipt at the laboratory. No request, for any of the above, will be entertained after the due date.

Reference

- i) Rosai and Ackerman's Surgical Pathology.
- ii) Modern Surgical Pathology.

Gulshan Yadav, MD
Consultant Pathologist