

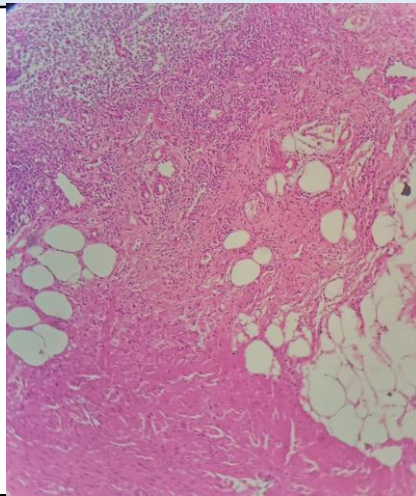
Patient Name	Mr. VIVEK	Client Name	Path Star Diagnostic	Specimen Received	03-Oct-19
Age/Sex	22Years/Male			Specimen Type	Tissue
Patient ID	011910030216			Collection Date	03-Oct-19
Specimen ID	MOLQ/B-1895/19			Report Date	05-Oct-19

SURGICAL PATHOLOGY REPORT

Appendix

DIAGNOSIS

ACUTE APPENDICITIS



SPECIMEN

Appendix

GROSS

Received 4.8x2.9 cm long appendix. Cut section shows feco-lith with 3x2.8cm multiple bits.

Microscopy

1. Section examined shows lymphoid follicles with ulcerative mucosa. Deeper tissue shows inflammatory cells (polymorphs and lymphocytes). No granuloma seen. No malignant cells seen.

Note : All biopsy specimen will be stored for 15 (fifteen)days, block and slides for 5(five) years only from the time of receipt at the laboratory. No request ,for any of the above ,will be entertained after the due date.

Reference

- i) Rosai and Ackerman's Surgical Pathology.
- ii) Modern Surgical Pathology.

Gulshan Yadav, MD
Consultant Pathologist