

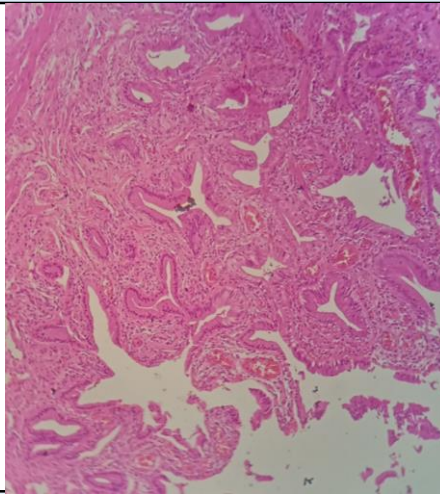
Patient Name	Mrs. SANTOSH	Client Name	Kriti Hospital	Specimen Received	03-Oct-19
Age/Sex	45Years/Female			Specimen Type	Tissue
Patient ID	011910030174			Collection Date	03-Oct-19
Specimen ID	MOLQ/B-1893/19			Report Date	05-Oct-19

SURGICAL PATHOLOGY REPORT

Gall Bladder

DIAGNOSIS

CHOLECYSTITIS.



SPECIMEN

Gall Bladder

GROSS

Received 11x2.7cm long gall bladder wall thickness 0.2mm without stones.

Microscopy

1. Section examined shows ulcerative mucosa and Rokitansky Aschoff sinus (irregularly shaped tubular structures lined by cuboidal lining epithelium with round to oval nucleus) with fibro collagenous tissue and inflammatory cells (lymphocytes). NO granuloma and no malignant cells seen.

Note : All biopsy specimen will be stored for 15 (fifteen) days, block and slides for 5 (five) years only from the time of receipt at the laboratory. No request, for any of the above, will be entertained after the due date.

Reference

- i) Rosai and Ackerman's Surgical Pathology.
- ii) Modern Surgical Pathology.



Gulshan Yadav, MD
Consultant Pathologist