

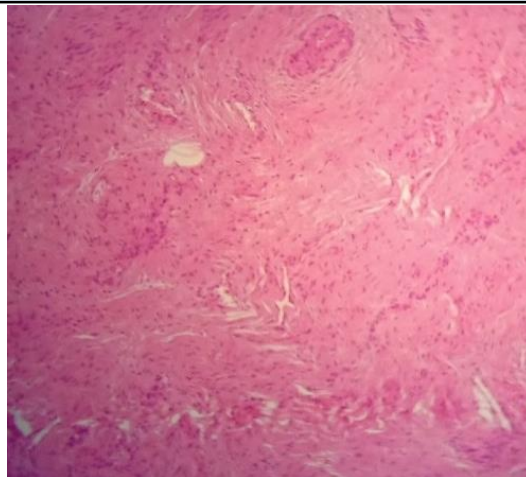
<b>Patient Name</b>	Ms. SHOBHA SHARMA	<b>Client Name</b>	Lifeaid Wellness Centre	<b>Specimen Received</b>	01-10-19
<b>Age/Sex</b>	40 YRS/F	(Rewari)		<b>Specimen Type</b>	Tissue
<b>Patient ID</b>	011910020058			<b>Collection Date</b>	01-10-19
<b>Specimen ID</b>	MOLQ/B-1887/19(1)			<b>Report Date</b>	04-10-2019

## SURGICAL PATHOLOGY REPORT

Endometrial polyp

### DIAGNOSIS

Endometrial Polyp.



#### SPECIMEN

Endometrial polyp

#### GROSS

Received 0.5x0.5cm grayish white tissue piece.

#### Microscopy

Section examined shows small and cystically dilated endometrial glands with columnar lining epithelium having round to oval nucleus. Stroma shows mononuclear inflammatory cells. No granuloma and no malignant cells seen.

**Note :** All biopsy specimen will be stored for 15 (fifteen)days, block and slides for 5(five) years only from the time of receipt at the laboratory. No request ,for any of the above ,will be entertained after the due date.

#### Reference

- i) Rosai and Ackerman's Surgical Pathology.
- ii) Modern Surgical Pathology.

**Gulshan Yadav, MD**  
Consultant Pathologist