

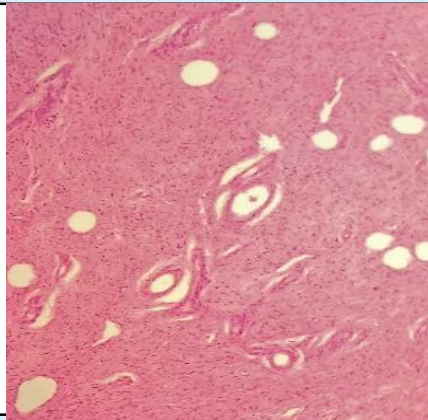
Patient Name	Miss. NUSRAT / WUYAN	Client Name	A-One Collection	Specimen Received	30/09/19
Age/Sex	16 Years/Female		Centre, Jammu & Kashmir	Specimen Type	Tissue
Patient ID	041909300005			Collection Date	30/09/19
Specimen ID	MOLQ/B-1874/19			Report Date	03/10/19

SURGICAL PATHOLOGY REPORT

Cystic swelling of left side buttock.

DIAGNOSIS

Benign Mesenchymal Lesion.



SPECIMEN

Cystic swelling of left side buttock.

GROSS

Received 2x1.9cm grayish white tissue piece.

Microscopy

Section examined shows fibro collagenous tissue ,ducts lined by cuboidal lining epithelium with small round nucleus. No granuloma and no malignant cells seen.

Note : All biopsy specimen will be stored for 15 (fifteen)days, block and slides for 5(five) years only from the time of receipt at the laboratory. No request ,for any of the above ,will be entertained after the due date.

Reference

- i) Rosai and Ackerman's Surgical Pathology.
- ii) Modern Surgical Pathology.

Gulshan Yadav, MD
Consultant Pathologist