

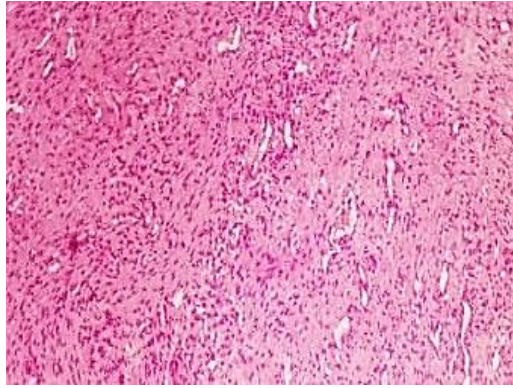
| | | | | | |
|---------------------|-----------------|---------------|----------------------|--------------------------|----------|
| Patient Name | Ms. KAVITA | Client | Path Star Diagnostic | Specimen Received | 28/09/19 |
| Age/Sex | 26 Years/Female | | | Specimen Type | Tissue |
| Patient ID | 011909270242 | | | Collection Date | 28/09/19 |
| Specimen ID | MOLQ/B-1863/19 | | | Report Date | 01/10/19 |

SURGICAL PATHOLOGY REPORT

- (1) Left ovarian cyst.
(2) Right Ovarian cyst.

DIAGNOSIS

- (1) Simple Ovarian Cyst.**
(2) Endometriotic cyst.



SPECIMEN

- (1) Left ovarian cyst.
(2) Right Ovarian cyst.

GROSS

- (1) Received 3x3cm grayish white tissue piece.
(2) Received 3.2x3.5cm grayish white tissue piece.

Microscopy

(1) Section examined shows ovarian tissue with cyst lining epithelium round nucleus, blood vessels. No granuloma and no malignant cells seen.

(2) Ovarian tissue with large number of blood vessels glands lined by columnar lining epithelium with round to oval nucleus. No granuloma and no malignant cells seen.

Note : All biopsy specimen will be stored for 15 (fifteen) days, block and slides for 5 (five) years only from the time of receipt at the laboratory. No request ,for any of the above ,will be entertained after the due date.

Reference

- i) Rosai and Ackerman's Surgical Pathology.
ii) Modern Surgical Pathology.

Gulshan Yadav, MD
Consultant Pathologist