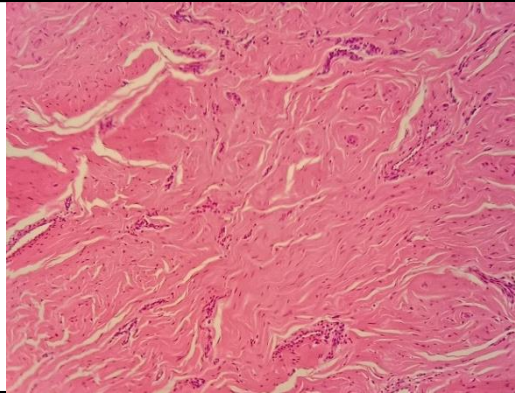


Patient Name	Ms. RENU DEVI	Client	Civil Hospital Sec-10	Specimen Received	28/09/19
Age/Sex	24 Years/Female			Specimen Type	Tissue
Patient ID	011909280264			Collection Date	28/09/19
Specimen ID	MOLQ/B-1868/19			Report Date	01/10/19

SURGICAL PATHOLOGY REPORT Gall Bladder

DIAGNOSIS

CHOLECYSTITIS AND CHOLELITHIASIS.



SPECIMEN

Gall Bladder

GROSS

Received 6.1x2.3 cm long gall bladder. Cut section shows stones.


Microscopy

Section examined shows ulcerative mucosa and Rokitansky-Aschoff sinuses (irregularly shaped tubular structures lined by cuboidal lining epithelium with round to oval nucleus) with fibrocollagenous tissue and inflammatory cells (lymphocytes). No granuloma and no malignant cells seen.

Note : All biopsy specimen will be stored for 15 (fifteen) days, block and slides for 5 (five) years only from the time of receipt at the laboratory. No request, for any of the above, will be entertained after the due date.

Reference

- i) Rosai and Ackerman's Surgical Pathology.
- ii) Modern Surgical Pathology.


Gulshan Yadav, MD
Consultant Pathologist