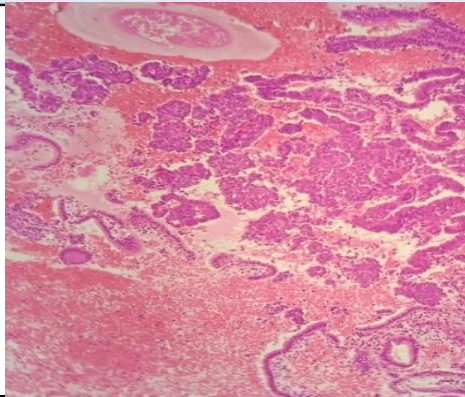


Patient Name	Mrs. MITHLESH 39613	Client	Pushpanjali Hospital (Rewari)	Specimen Received	27/09/19
Age/Sex	31 Years/Female			Specimen Type	Tissue
Patient ID	011909270287			Collection Date	27/09/19
Specimen ID	MOLQ/B-1865/19			Report Date	01/10/19

SURGICAL PATHOLOGY REPORT Endometrium

DIAGNOSIS

Simple Hyperplasia Without Atypia



SPECIMEN

Endometrium

GROSS

Received multiple grayish white tissue piece.

Microscopy

Section examined shows small and cystically dilated endometrial glands with RBCs in the background stroma shows mononuclear inflammatory cells.

No granuloma and no malignant cells seen

Note : All biopsy specimen will be stored for 15 (fifteen) days, block and slides for 5 (five) years only from the time of receipt at the laboratory. No request, for any of the above, will be entertained after the due date.

Reference

- i) Rosai and Ackerman's Surgical Pathology.
- ii) Modern Surgical Pathology.

Gulshan Yadav, MD
Consultant Pathologist