

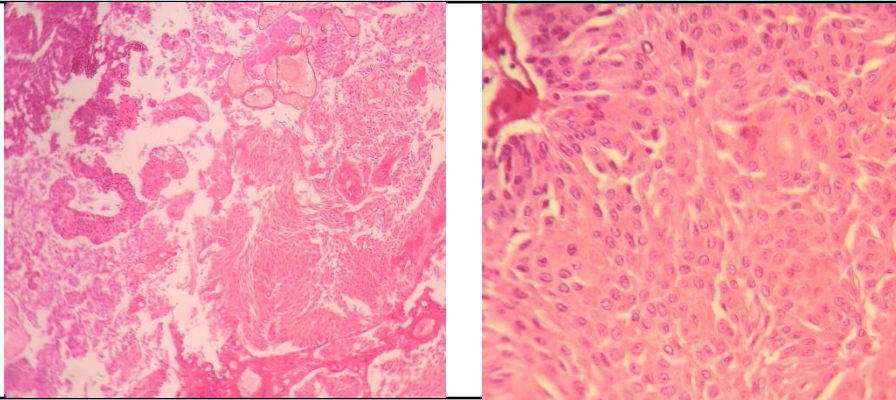
Patient Name	Mr. RAGHVIR 39581	Client Name	Pushpanjali Hospital (Rewari)	Specimen Received	27-Sep-2019
Age/Sex	73 Years/Male			Specimen Type	Tissue
Patient ID	011909270284			Collection Date	27-Sep-2019
Specimen ID	MOLQ/B-1864/19			Report Date	01-Oct-2019

SURGICAL PATHOLOGY REPORT

TURBT

DIAGNOSIS

LOW GRADE UROTHELIAL CARCINOMA



SPECIMEN

TURBT

GROSS

Received multiple grayish white tissue piece, 6x5 cm in aggregate.

Microscopy

Histologic Type:

Urothelial (Transitional Cell) Carcinoma.

Low Grade.

Tumor Configuration:

Solid / Nodule.

Adequacy of Material for Determining Muscularis Propria Invasion.

Muscularis Propria Invasion (Detrusor Muscle):

Invaded.

Lymph vascular Invasion:

Not invaded.

Microscopic extent of tumor:

Tumor invaded subepithelial connective tissue (lamina propria).

Muscularis propria is invaded.

Detrusor muscle not invaded

Note : All biopsy specimen will be stored for 15 (fifteen) days, block and slides for 5 (five) years only from the time of receipt at the laboratory. No request, for any of the above, will be entertained after the due date.

Reference

- i) Rosai and Ackerman's Surgical Pathology.
- ii) Modern Surgical Pathology.

Gulshan Yadav, MD
Consultant Pathologist