

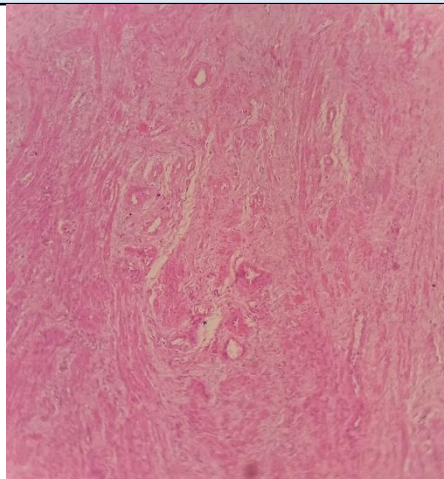
Patient Name	Mrs. SURESH W/O SATBIR SINGH	Client Name	Path Star Diagnostic	Specimen Received	26-Sep-19
Age/Sex	47 YRS/FF			Specimen Type	Tissue
Patient ID	011909260245			Collection Date	26-Sep-19
Specimen ID	MOLQ/B-1858/19			Report Date	30-Sep-2019

SURGICAL PATHOLOGY REPORT

Uterus with Cervix

DIAGNOSIS

CHRONIC CERVICITIS



SPECIMEN

Uterus with Cervix

GROSS

Received 8.2x6 cm uterus with cervix with bilateral adnexa. Ovary size 2x3 cm, 3x2 cm. Cut section from the ovary shows blood clot. Cut section from other ovary multiloculated cyst with clear fluid. Fibroid not seen.

Microscopy

Section examined shows

- 1) Endometrium with proliferative phase
- 2) Myometrium with superficial adenomyosis.
- 3) Cervix with mononuclear inflammatory cells
- 4) Ovary with hemorrhagic cyst and tube unremarkable
- 5) Other ovary with simple cyst and tube unremarkable

Note : All biopsy specimen will be stored for 15 (fifteen) days, block and slides for 5 (five) years only from the time of receipt at the laboratory. No request, for any of the above, will be entertained after the due date.

Reference

- i) Rosai and Ackerman's Surgical Pathology.
- ii) Modern Surgical Pathology.

A handwritten signature in black ink, appearing to read 'Gulshan', written over a light blue rectangular background.

Gulshan Yadav, MD
Consultant Pathologist