

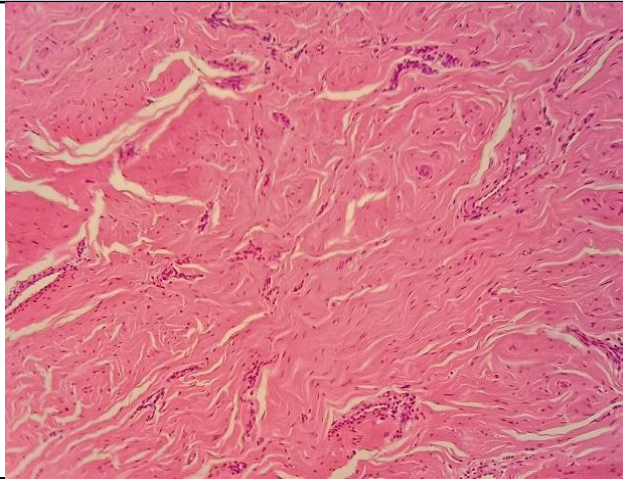
Patient Name	Mr. RAJESH KUMAR	Client Name	Cygnus SuperSpeciality	Specimen Received	25-Sep-19
Age/Sex	47 Years/Male		Hospital, Rewari	Specimen Type	Tissue
Patient ID	011909250252			Collection Date	25-Sep-19
Specimen ID	MOLQ/B-1856/19			Report Date	28-Sep-2019

SURGICAL PATHOLOGY REPORT

Gall Bladder

DIAGNOSIS

CHOLECYSTITIS AND CHOLELITHIASIS.



SPECIMEN

Gall Bladder

GROSS

Received 5.4x2.5cm long gall bladder already cut open with stones wall thickness 0.3mm.

Microscopy

Section examined shows ulcerative mucosa and Rokitansky-Aschoff sinus (irregularly shaped tubular structures lined by cuboidal lining epithelium with round to oval nucleus) with fibrocollagenous tissue and inflammatory cells (lymphocytes).

Note : All biopsy specimen will be stored for 15 (fifteen) days, block and slides for 5 (five) years only from the time of receipt at the laboratory. No request, for any of the above, will be entertained after the due date.

Reference

- i) Rosai and Ackerman's Surgical Pathology.
- ii) Modern Surgical Pathology.

Gulshan Yadav, MD
Consultant Pathologist