

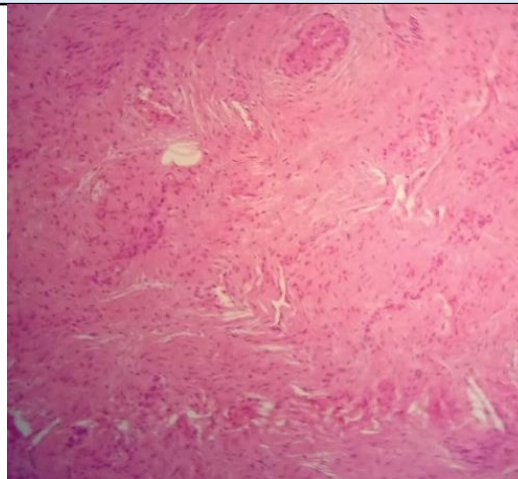
Patient Name	Mrs. ASTHA DEVI	Client Name	Path Star Diagnostic	Specimen Received	24-Sep-19
Age/Sex	41 YRS/F			Specimen Type	Tissue
Patient ID	011909240255			Collection Date	24-Sep-19
Specimen ID	MOLQ/B-1849/19			Report Date	28-Sep-2019

SURGICAL PATHOLOGY REPORT

Cervical polyp

DIAGNOSIS

Endocervical polyp.



SPECIMEN

Cervical polyp

GROSS

Received two grayish white tissue piece measuring 1x1cm.

Microscopy

Section examined shows endocervical glands with columnar lining epithelium round to oval nucleus. Stroma shows mononuclear inflammatory cells and blood vessels. No granuloma and no malignant cells seen.

Note : All biopsy specimen will be stored for 15 (fifteen)days, block and slides for 5(five) years only from the time of receipt at the laboratory. No request ,for any of the above ,will be entertained after the due date.

Reference

- i) Rosai and Ackerman's Surgical Pathology.
- ii) Modern Surgical Pathology.

Gulshan Yadav, MD
Consultant Pathologist