

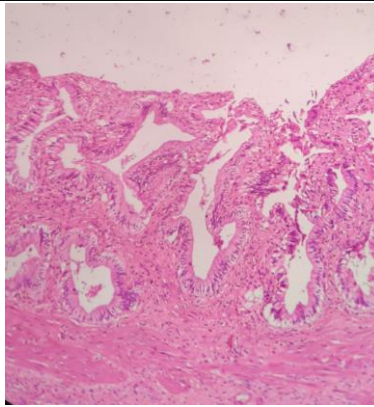
Patient Name	Mr. MOHAMMED GAHAR GHAFI	Specimen Received	23-Sep-2019
Age/Sex	76 Years/Male	Specimen Type	Tissue
Patient ID	011909230347	Client Name	Lifeaid Wellness Center
Specimen ID	MOLQ/B-1842/19	Collection Date	23-Sep-2019
		Report Date	27-Sep-2019

SURGICAL PATHOLOGY REPORT

Gall Bladder

DIAGNOSIS

CHOLECYSTITIS.



SPECIMEN

Gall Bladder

GROSS

Received 7x2.6 cm long gall bladder already cut open without stones.

Microscopy

- Section examined shows ulcerative mucosa and Rokitansky-Aschoff sinuses (irregularly shaped tubular structures lined by cuboidal lining epithelium with round to oval nucleus) with fibrocollagenous tissue and inflammatory cells (lymphocytes).

Note : All biopsy specimen will be stored for 15 (fifteen) days, block and slides for 5 (five) years only from the time of receipt at the laboratory. No request, for any of the above, will be entertained after the due date.

Reference

- Rosai and Ackerman's Surgical Pathology.
- Modern Surgical Pathology.

Gulshan Yadav, MD
Consultant Pathologist