

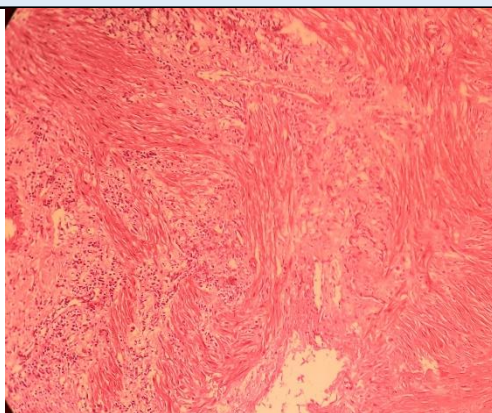
Patient Name	Ms Varsha	Client Name	Cygnus Super	Specimen Received	23-Sep-2019
Age/Sex	19 Years/Female		Speciality Hospital,	Specimen Type	Tissue
Patient ID	011909230312		Rewari	Collection Date	23-Sep-2019
Specimen ID	MOLQ/B-1837/19			Report Date	27-Sep-2019

SURGICAL PATHOLOGY REPORT

Gall Bladder

DIAGNOSIS

CHOLECYSTITIS AND CHOLELITHIASIS.



SPECIMEN

Gall Bladder

GROSS

Received autolyzed 6.2x2.6 cm long gall bladder already cut open with shows stones. Wall Thickness 0.5 mm

Microscopy

1. Section examined shows autolytic changes in the tissue with ulcerative mucosa and rokitansky aschoff sinus (irregularly shaped tubular structures lined by cuboidal lining epithelium with round to oval nucleus) with fibro collagenous tissue and inflammatory cells (lymphocytes).

Note : All biopsy specimen will be stored for 15 (fifteen)days, block and slides for 5(five) years only from the time of receipt at the laboratory. No request ,for any of the above ,will be entertained after the due date.

Reference

- i) Rosai and Ackerman's Surgical Pathology.
- ii) Modern Surgical Pathology.

Gulshan Yadav, MD
Consultant Pathologist