

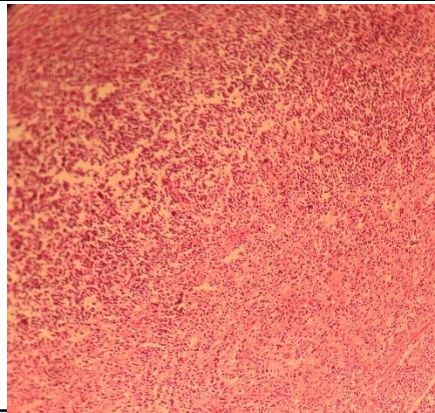
Patient Name	Baby. AADIBA	Client Name	Galaxy Hospital, Palwal	Specimen Received	23-Sep-2019
Age/Sex	11 Years/Female			Specimen Type	Tissue
Patient ID	011909230281			Collection Date	23-Sep-2019
Specimen ID	MOLQ/B-1836/19			Report Date	27-Sep-2019

SURGICAL PATHOLOGY REPORT

Left Lateral Thigh (Dermatopyomyositis)

DIAGNOSIS

INFECTIVE LESION WITH GRANULATION TISSUE



SPECIMEN

Left Lateral Thigh (Dermatopyomyositis))

GROSS

Received multiple grayish white tissue piece, 2x1 cm in aggregate.

Microscopy

1. Section examined shows fibrocollagenous tissue and blood vessels, inflammatory cells (chiefly composed of Lymphocytes, Plasma Cells, Polymorphs and Histiocytes), areas of necrosis.
2. No granuloma seen.
3. No malignant cells seen..

Note : All biopsy specimen will be stored for 15 (fifteen)days, block and slides for 5(five) years only from the time of receipt at the laboratory. No request ,for any of the above ,will be entertained after the due date.

Reference

- i) Rosai and Ackerman's Surgical Pathology.
- ii) Modern Surgical Pathology.

Gulshan Yadav, MD
Consultant Pathologist