

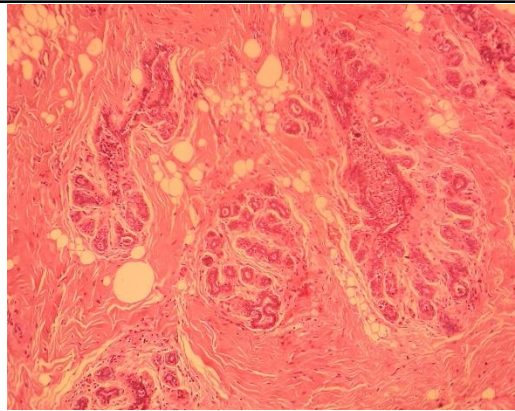
Patient Name	Ms Manu	Client Name	Expert Healthcare	Specimen Received	23-Sep-2019
Age/Sex	20 Years/Female		Centre	Specimen Type	Tissue
Patient ID	011909230169			Collection Date	23-Sep-2019
Specimen ID	MOLQ/B-1835/19			Report Date	27-Sep-2019

SURGICAL PATHOLOGY REPORT

Fibroadenoma (Bilateral Breast)

DIAGNOSIS

BENIGN BREAST LESION



SPECIMEN

Fibroadenoma (Bilateral Breast)

GROSS

Received 4x5 cm greyish white tissue piece in aggregate.

Microscopy

1. Section examined shows ducts (few cystically dilated) with cuboidal epithelium with small round nucleus surrounded by fibro collagenous tissue.
2. No granuloma seen. No malignant cells seen.

Note : All biopsy specimen will be stored for 15 (fifteen) days, block and slides for 5 (five) years only from the time of receipt at the laboratory. No request, for any of the above, will be entertained after the due date.

Reference

- i) Rosai and Ackerman's Surgical Pathology.
- ii) Modern Surgical Pathology.

Gulshan Yadav, MD
Consultant Pathologist