

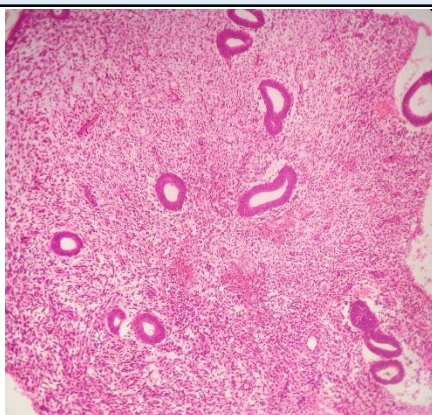
<b>Patient Name</b>	<b>Mrs. KARIMA BIBI</b>	<b>Client Name</b>	Brijanand Path Lab	<b>Specimen Received</b>	22-Sep-2019
<b>Age/Sex</b>	35 Years/Female			<b>Specimen Type</b>	Tissue
<b>Patient ID</b>	011909220213			<b>Collection Date</b>	22-Sep-2019
<b>Specimen ID</b>	MOLQ/B-1832/19			<b>Report Date</b>	27-Sep-2019

## SURGICAL PATHOLOGY REPORT

### Endometrial curetting

#### DIAGNOSIS

### SIMPLE HYPERPLASIA WITHOUT ATYPIA



#### SPECIMEN

Endometrial Curetting

#### GROSS

Received multiple greyish white tissue piece.

#### Microscopy

1. Section examined shows small with cystically dilated glands with cuboidal to columnar lining epithelium with round to oval nucleus.
2. Stroma shows mononuclear inflammatory cells.
3. No granuloma and no malignant cells seen.

**Note :** All biopsy specimen will be stored for 15 (fifteen)days, block and slides for 5(five) years only from the time of receipt at the laboratory. No request ,for any of the above ,will be entertained after the due date.

#### Reference

- i) Rosai and Ackerman's Surgical Pathology.
- ii) Modern Surgical Pathology.

**Gulshan Yadav, MD**  
Consultant Pathologist