

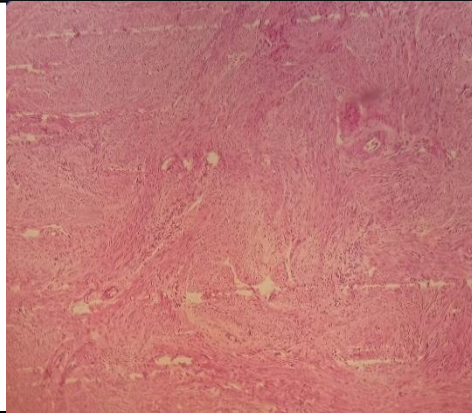
<b>Patient Name</b>	<b>Mrs. SUMAN 39461</b>	<b>Client</b> Pushpanjali Hospital	<b>Specimen Received</b>	21-Sep-2019
<b>Age/Sex</b>	42 Years/Female	(Rewari)	<b>Specimen Type</b>	Tissue
<b>Patient ID</b>	011909210354		<b>Collection Date</b>	21-Sep-2019
<b>Specimen ID</b>	MOLQ/B-1827/19		<b>Report Date</b>	27-Sep-2019

## SURGICAL PATHOLOGY REPORT

Endometrium

### DIAGNOSIS

**PROLIFERATIVE PHASE**



#### SPECIMEN

Endometrium

#### GROSS

Received multiple grayish white tissue piece.

#### Microscopy

Section examined shows small endometrial glands with cuboidal lining with small round nucleus. Stroma shows mononuclear inflammatory cells.

No granuloma seen. No malignant cells seen.

**Note :** All biopsy specimen will be stored for 15 (fifteen) days, block and slides for 5 (five) years only from the time of receipt at the laboratory. No request, for any of the above, will be entertained after the due date.

#### Reference

- i) Rosai and Ackerman's Surgical Pathology.
- ii) Modern Surgical Pathology.

**Gulshan Yadav, MD**  
**Consultant Pathologist**