

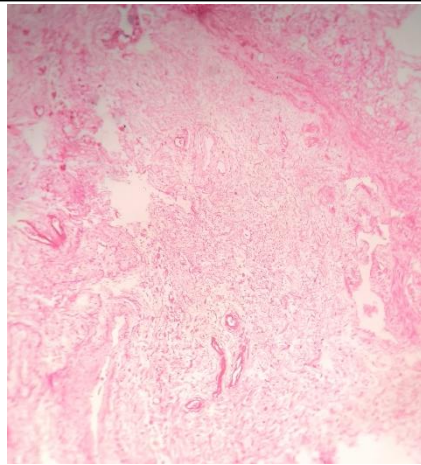
Patient Name	Mr. GHISA RAM 38243	Client Name	Pushpanjali Hospital (Rewari)	Specimen Received	21-Sep-2019
Age/Sex	90 Years/Male			Specimen Type	Tissue
Patient ID	011909210352			Collection Date	21-Sep-2019
Specimen ID	MOLQ/B-1826/19			Report Date	27-Sep-2019

SURGICAL PATHOLOGY REPORT

Internal Hemorrhoids with Rectal Mucosa

DIAGNOSIS

HEMORRHOIDS



SPECIMEN

Internal Hemorrhoids with Rectal Mucosa

GROSS

Received 6x3 cm greyish white tissue piece already cut open.

Microscopy

- Section examined shows mucosal lining epithelium and submucosal glands. Stroma shows inflammatory cells and blood vessels.
- No granuloma seen. No malignant cells seen.

Note : All biopsy specimen will be stored for 15 (fifteen)days, block and slides for 5(five) years only from the time of receipt at the laboratory. No request ,for any of the above ,will be entertained after the due date.

Reference

- Rosai and Ackerman's Surgical Pathology.
- Modern Surgical Pathology.

Gulshan Yadav, MD
Consultant Pathologist