

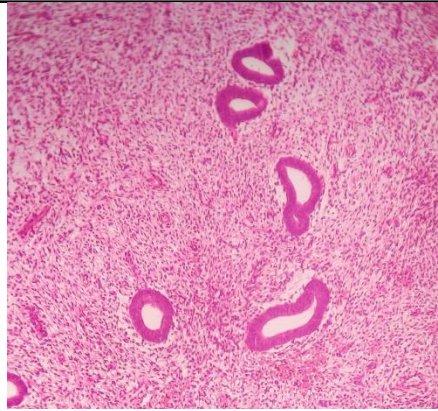
Patient Name	Mrs. Meena	Client Name	Civil Hospital Sec-10	Specimen Received	21-Sep-2019
Age/Sex	33 Years/Female			Specimen Type	Tissue
Patient ID	011909210247			Collection Date	21-Sep-2019
Specimen ID	MOLQ/B-1822/19			Report Date	27-Sep-2019

SURGICAL PATHOLOGY REPORT

Endometrium

DIAGNOSIS

DISORDERED PROLIFERATIVE PHASE



SPECIMEN

Endometrium

GROSS

Received multiple greyish white tissue piece.

Microscopy

1. Section examined shows small and tortous endometrial glands with columnar lining with small round nucleus with tufting in the lumen.
2. Stroma shows mononuclear inflammatory cells.
3. No granuloma seen. No malignant cells seen.

Note : All biopsy specimen will be stored for 15 (fifteen) days, block and slides for 5 (five) years only from the time of receipt at the laboratory. No request, for any of the above, will be entertained after the due date.

Reference

- i) Rosai and Ackerman's Surgical Pathology.
- ii) Modern Surgical Pathology.

A handwritten signature in black ink, appearing to read 'Gulshan', written over a light blue rectangular background.

**Gulshan Yadav, MD
Consultant Pathologist**