

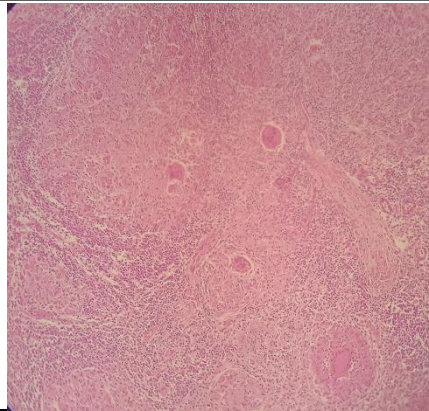
Patient Name	Mr. KUNDAN	Client Name	Vedic Hospital	Specimen Received	21-Sep-2019
Age/Sex	13 Years/Male			Specimen Type	Tissue
Patient ID	011909210176			Collection Date	21-Sep-2019
Specimen ID	MOLQ/B-1818/19			Report Date	26-Sep-2019

SURGICAL PATHOLOGY REPORT

Cervical Lymphadenopathy (Side not mentioned)

DIAGNOSIS

GRANULOMATOUS LYMPHADENITIS
(SUGGESTIVE OF TUBERCULAR PATHOLOGY)



SPECIMEN

Cervical Lymphadenopathy
(Side not mentioned)

GROSS

Received 2.4x2.3 cm greyish white tissue piece.

Microscopy

Section examined shows preserved architecture lymphoid follicles with presence of formation of epithelioid cell granuloma, multinucleated giant cells and necrosis.
No malignant cells seen.

Note : All biopsy specimen will be stored for 15 (fifteen)days, block and slides for 5(five) years only from the time of receipt at the laboratory. No request ,for any of the above ,will be entertained after the due date.

Reference

- i) Rosai and Ackerman's Surgical Pathology.
- ii) Modern Surgical Pathology.

Gulshan Yadav, MD
Consultant Pathologist