

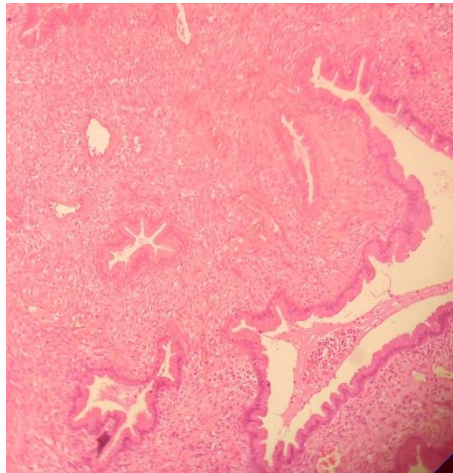
Patient Name	Mr. RAM SURAT CHAURASIA	Client Name	Welcome Hospital Delhi	Specimen Received	20-Sep-2019
Age/Sex	40 Years/Male			Specimen Type	Tissue
Patient ID	011909200110			Collection Date	20-Sep-2019
Specimen ID	MOLQ/B-1809/19			Report Date	25-Sep-2019

SURGICAL PATHOLOGY REPORT

Swelling on the palm

DIAGNOSIS

Benign Mesenchymal Lesion



SPECIMEN

Swelling on the palm

GROSS

Received 2x1cm grayish white tissue piece.

Microscopy

1. Section examined shows fibro collagenous tissue arranged in bundles and in fascicles with blood vessels. Stroma mononuclear inflammatory cells.
2. No granuloma and no malignant cells seen.

Note : All biopsy specimen will be stored for 15 (fifteen)days, block and slides for 5(five) years only from the time of receipt at the laboratory. No request ,for any of the above ,will be entertained after the due date.

Reference

- i) Rosai and Ackerman's Surgical Pathology.
- ii) Modern Surgical Pathology.

Gulshan Yadav, MD
Consultant Pathologist